

OLGU SUNUMU – CASE REPORT

UNEXPECTED SUBGLOTTIC STENOSIS IN A NEWBORN IN ANESTHESIA INDUCTION

YENİDOĞANDA ANESTEZİ İNDÜKSİYONUNDA BEKLENMEYEN SUBGLOTİK STENOZ

Şennur UZUN¹, Oğuzhan ARUN², Turgay ÖCAL¹

¹Hacettepe Üniversitesi Tıp Fakültesi Anesteziyoloji ve Reanimasyon AD, Ankara

²Selçuk Üniversitesi Tıp Fakültesi Anesteziyoloji ve Reanimasyon AD, Konya

¹Hacettepe University Faculty of Medicine Department of Anesthesiology and Reanimation, Turkey

²Selçuk University Faculty of Medicine Department of Anesthesiology and Reanimation, Turkey

ABSTRACT

An unexpected subglottic stenosis in a neonate with multiple congenital anomalies who was scheduled for an emergency surgery of duodenal atresia was described in this case report. Duodenal atresia was diagnosed on the first day of life. After induction with sevoflurane, despite good view of the vocal cords, it was not possible to advance endotracheal tube beyond the vocal cords. After a flexible fiberoptic examination, subglottic stenosis was diagnosed and ‘an emergency tracheostomy’ decision was taken. The urgency of the operation and patent postoperative airway requirement are the key points which influence this decision.

KEY WORDS: Subglottic stenosis, newborn, duodenal atresia

ÖZET

Multipl konjenital anomalili bir yenidoğan, doğumdan sonraki ilk gün teşhis edilen duodenal atrezisi için acil operasyona alınmış ve anestezi indüksiyonunda entübasyon sırasında subglotik stenoz ile karşılaşmış. Sevofluran ile indüksiyon sonrası vokal kordlar güzel görülmesine rağmen endotrakeal tüp ilerletilememiştir. Acil flexible fiberoptik bronkoskopi muayene edilerek subglotik stenoz teşhisi koyulmuştur. Ameliyatın aciliyetinden dolayı ‘acil trakeostomi’ kararı alınarak cerrahiye devam edilmiştir. Bu kararda cerrahinin aciliyeti ve postoperatif sağlam bir havayolu ihtiyacı etkili olmuştur.

ANAHTAR KELİMELELER: Subglotik stenoz, yenidoğan, duodenal atrezi

INTRODUCTION

Subglottic stenosis (SGS) is one of the most common causes of airway obstruction in infants and children. It is the second most common cause of stridor in infants and the most common laryngotracheal anomaly requiring tracheostomy in children under 1 year of age [1]. We report the anesthetic management of an unexpected SGS in a 1 day aged newborn.

CASE REPORT

A female neonate was born with a birth weight of 2440 g from a 29-years-old gravida 1, parity 1 mother via caesarean section at 38th week of gestation. Tetralogy of Fallot, single umbilical artery, bilateral renal-pelvic dilatation and anal atresia were diagnosed in a routine prenatal USG follow up. The family history was unremarkable with no known consanguinity. After birth,

heart rate decreased to 60 min⁻¹ that was stabilized after suctioning and bag mask ventilation. The Apgar scores were 8 and 9 at 1st and 5th min, respectively. The baby was transferred to the neonatal intensive care unit because of cardiac and renal malformations. Oxygen saturation was maintained with supplemental oxygen and there has been no need for intubation. The postnatal abdominal X-ray film showed a ‘double-bubble’ sign and dilated intestinal loops which were consistent with the diagnosis of duodenal atresia. The baby was scheduled for an urgent laparotomy on the 1st day of life for correction of congenital duodenal obstruction.

Before induction of anesthesia, the baby was pre-oxygenated with 100% oxygen. SpO₂ remained constant, over 96% and neither respiratory distress nor inspiratory stridor has been noted. Anesthesia was induced

Çıkar çatışması/Conflict of Interest: Yazarlar herhangi bir çıkar çatışması bildirmemişlerdir./ Authors do not report any conflict of interest.

Geliş tarihi/Received: 06/03/2014

Kabul tarihi/Accepted: 29/05/2014

Yazışma Adresi (Correspondence):

Dr. Şennur UZUN, Hacettepe Üniversitesi Tıp Fakültesi Anesteziyoloji ve Reanimasyon AD, Sıhhiye, Ankara

e-posta (e-mail): sennuruzun1@gmail.com

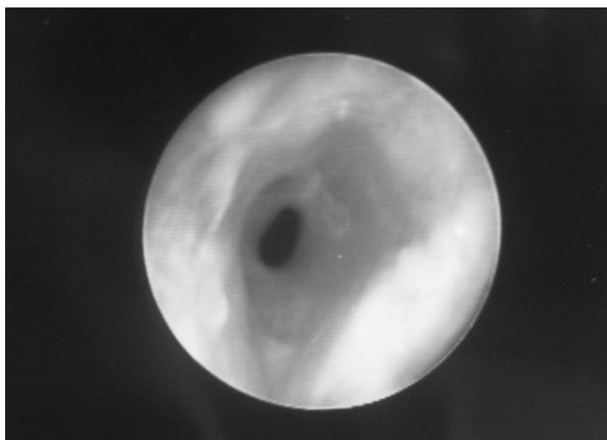


Figure 1: Flexible fiberoptic laryngoscopic view of the subglottic stenosis.

with sevoflurane 8% in 100% oxygen. SpO₂ maintained at 99%. Then the baby was given 1 mg.kg⁻¹ fentanyl and 0.5 mg.kg⁻¹ rocuronium bromide, intravenously. Despite good view of the vocal cords, it was not possible to advance 3.0 mm, 2.5 mm and 2.0 mm internal diameter tubes beyond vocal cords because of resistance. Ear-nose and throat (ENT) consultant was invited to the operating room immediately for direct flexible fiberoptic laryngoscopy and grade-3 subglottic stenosis was diagnosed (Figure 1). The options for airway management were discussed with ENT and Pediatric surgery consultants and ‘an emergency conventional tracheostomy’ decision was found suitable because of the urgency of the operation. The otorhinolaryngologist performed a formal tracheostomy successfully and anesthesia was maintained with 50% O₂-air and 2% sevoflurane under controlled ventilation.

After an uneventful sigmoid loop ostomy and duodenostomy which lasted for four hours, the baby was transferred to the neonatal intensive care unit with bag mask ventilation through the tracheostomy cannula.

DISCUSSION

Congenital subglottic stenosis is the third most common congenital laryngeal anomaly, after laryngomalacia and vocal fold paralysis [1]. The estimated incidence of congenital pediatric subglottic stenosis is 5% of all cases and below 1% when very low birth weight infants are excluded [1, 2]. The majority of the cases of subglottic stenosis are acquired, most commonly associated with prolonged endotracheal tube intubation, laryngopharyngeal reflux, infection and the associated inflammatory response and generally a congenital stenosis is less severe than acquired one [3].

The diameter of normal subglottic lumen is 4.5 to

5.5 mm in a full-term neonate and approximately 3.5 mm in a preterm baby. A subglottic airway diameter of 4 mm or less in a full-term infant or 3 mm or less in a premature infant is considered narrow and consistent with a diagnosis of subglottic stenosis [1]. Several staging systems have been created to describe and guide treatment options of subglottic stenosis and the Myer-Cotton system is one of the most reliable and widely used staging system [4].

Antenatal diagnosis of congenital airway obstruction syndrome is difficult. It is associated with normal larynx to the level of the vocal cords and little airway below this [5]. Failure to intubate beyond the vocal cords is frequently reported. Recurrent or persistent croup is typical, particularly in infants younger than 6 months. Although laryngeal anomalies frequently are first symptomatic, as a result of the inflammation caused by a common respiratory tract infection, our patient did not have any obstructive symptom as suprasternal and subcostal retractions, dyspnea or tachypnea. And we did not observe any inspiratory stridor, respiratory distress or saturation problem which could warn us about subglottic stenosis.

The presence of subglottic pathology in a child can be co-incidental with genetic syndromes or non-syndromic congenital anomalies such as esophageal and duodenal atresia [6], Down syndrome [7], VATER (vertebral, anorectal, tracheo-esophageal, and renal defects) syndrome [8], Fraser syndrome [9], Keutel syndrome [10]. The presence of a subglottic pathology should be kept in mind in a child with genetic syndromes or other non-syndromic congenital anomalies, especially when these involve the mediastinum, cardiovascular or esophageal anomalies. Our patient’s associated anomalies were tetralogy of fallot, single umbilical artery, bilateral renal-pelvic dilatation, duodenal and anal atresia.

When encountered in perioperative period, tracheostomy decision is hard to take, especially in newborns with congenital subglottic stenosis. The number of complications is higher during neonatal period. This can in part be explained by using smaller tubes and associated diseases. Fewer than 50% of children require a tracheotomy and most of them can be decannulated once the airway improves sufficiently [11]. In newborns, if the surgery is not urgent, the anesthesia should be postponed and management of subglottic stenosis should be planned in elective conditions [12]. In our case, as the surgery for duodenal atresia was urgent, we could not postpone the procedure.

As described in this case report, management of an unexpected subglottic stenosis in a newborn is critical

and the anesthetist should be aware of possible subglottic stenosis in babies with difficulties of intubation. Infants with multiple congenital anomalies may have subglottic stenosis although they have no any warning signs such as stridor or respiratory difficulty. In such situations, the urgency of the operation and postoperative safe airway requirement are the key points which influence the decision.

REFERENCES

1. Willging JP, Cotton RT. Subglottic stenosis in the pediatric patient. In: Myer CM, Cotton RT, Shott SR, editors. The pediatric airway. Philadelphia: JB Lippincott Co; 1995; p. 111-132.
2. Ratner I, Whitfield J. Acquired subglottic stenosis in the very low birth weight infant. Am J Dis Child 1983; 137: 40-43.
3. Schroeder JW Jr, Holinger LD. Congenital laryngeal stenosis. Otolaryngol Clin North Am 2008; 41: 865-875.
4. Myer CM, O'Conner DM, Cotton RT. Proposed grading system for subglottic stenosis based on endotracheal tube sizing. Ann Otol Rhinol Laryngol 1994; 103: 319-323.
5. Sato T, Nio M, Tanaka H, Ohi R. Prenatal diagnosis and management of congenital of congenital subglottic stenosis associated with congenital oesophageal atresia type c. Eur J Paediatr Surg 2008;18: 131-133.
6. Irving IM. Duodenal atresia and stenosis: annular pancreas. In: Lister J, Irving IM (eds) Neonatal surgery. Butterworths, London, 1990; pp 424*441.
7. Miller R., Gray S.D., Cotton R.T., Myer C.M., Netterville J. Subglottic stenosis and Down syndrome, Am J Otolaryngol 1990; 11: 274-277.
8. Corsello G, Maresi E, Corrao A.M et al., VATER/VACTERL association: clinical variability and expanding phenotype including laryngeal stenosis. Am J Genet 1992; 44: 813-815.
9. Ford GR., Irving RM, Jones NS, Bailey CM. ENT manifestations of Fraser syndrome, J Laryngol Otol 1992; 106: 1-4.
10. Meier M, Weng LP, Alexandrakis E, Ruschoff J, Goeckenjan G. Tracheobronchial stenosis in Keutel syndrome. Eur Respir J 2001; 17: 566-569.
11. Hartnick CJ, Cotton RT. Syndromic and other congenital anomalies of the head and neck. Otolaryngol Clin North Am 2003; 33: 1293-1308.
12. Asai T. Unexpected subglottic stenosis in an infant. Anaesthesia. 2006; 18: 126.